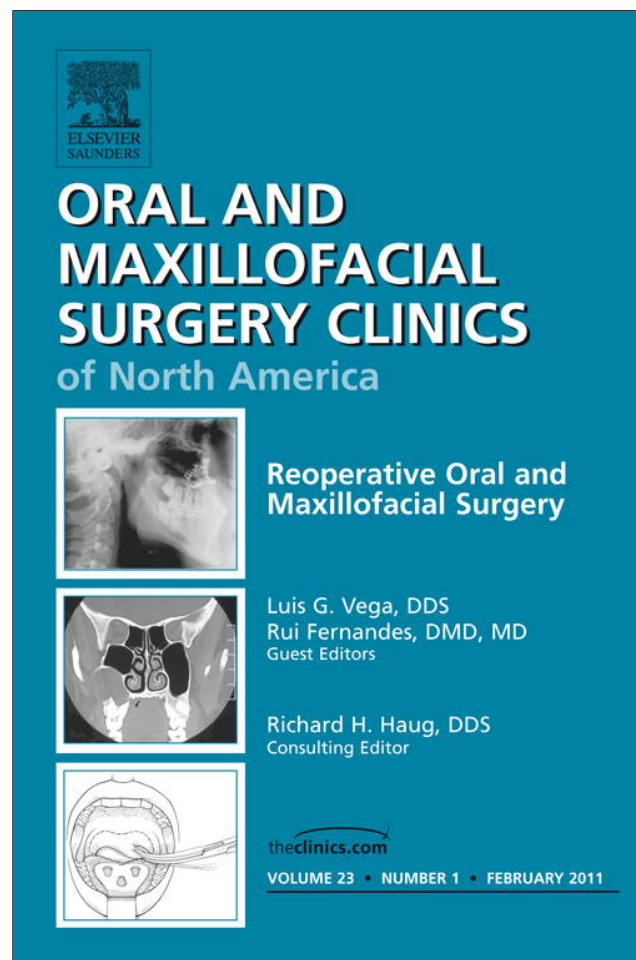

This article appeared in a journal published by Elsevier. The attached copy is furnished to the author for internal non-commercial research and education use, including for instruction at the authors institution and sharing with colleagues.

Other uses, including reproduction and distribution, or selling or licensing copies, or posting to personal, institutional or third party websites are prohibited.

In most cases authors are permitted to post their version of the article (e.g. in Word or Tex form) to their personal website or institutional repository. Authors requiring further information regarding Elsevier's archiving and manuscript policies are encouraged to visit:

<http://www.elsevier.com/copyright>

# Reoperative Face and Neck Lifts

Jacob Haiavy, MD, DDS<sup>a,b,\*</sup>

## KEYWORDS

- Secondary facelift • Revisional facelift • Reoperative facelift
- Secondary neck lift • Revisional neck lift
- Reoperative neck lift • Platysmaplasty
- Secondary rhytidectomy

In the past decade cosmetic surgery has become more common and accepted in our society. Face and neck lift procedures can be routinely viewed on the Internet or television. With easy access to the information and reality shows demonstrating success stories, there has been an increase in demand for these procedures. This increase has given rise to a new generation of patients who have undergone a facelift or a neck lift procedure and, because of the continued effects of aging, request a secondary operation.

When performing a secondary facelift or neck lift, the surgeon needs to consider the effects of the primary procedure on the tissues. Even though there are a few techniques of performing a facelift or a neck lift, the factors that need to be considered when performing a secondary procedure are the same:

- Previous incision placement and resulting scars
- Amount of skin laxity
- Earlobe deformity
- Hair pattern changes
- Fat irregularities and deficiencies
- Fascial laxity leading to deep nasolabial folds and jowls
- Cervicomental angle obtuseness
- Platysmal laxity and banding
- Presence of unusual rhytids.

Most patients requesting secondary facelifts or neck lifts have some form of laxity and want to maintain their facial appearance. In addition, most of the patients seeking secondary facelifts

are older in age and often have other ailments concomitant with aging. Therefore, the preoperative assessment should include a thorough medical history and physical examination. This assessment should include a history of over-the-counter and herbal medicines, because many of the patients who seek secondary facelift or neck lift take herbal medicine with potential ill effects on surgery. For example, ginkgo biloba and testosterone can potentially induce hypertension.<sup>1</sup> Many of the herbal products are blood thinners and can affect the coagulation cascade, such as ginkgo biloba, garlic tablets, ginger, St John's wort, and ginseng. The author recommends that patients stop all herbal medicines for 2 weeks before and after surgery. When necessary, appropriate referrals to the primary care physician, cardiologist, or other specialist should be made to obtain a clearance and minimize risk of perioperative complications.

In general, the author's approach to a secondary procedure is the opportunistic approach and is tailored to the patient's needs and existing anatomy.<sup>2</sup> Each patient presents with different skin thickness and elasticity, variable amount of subcutaneous tissue, variable amount of laxity and thickness of their superficial fascia, and variable amount of scarring from their primary facelift or neck lift. When evaluating the patient, the surgeon should look for residual signs of aging that have not been addressed in the primary procedure. It is not uncommon to see a patient who has had a facelift seeking a secondary procedure and on examination most of the laxity is

<sup>a</sup> Inland Cosmetic Surgery, 8680 Monroe Court, Suite #200, Rancho Cucamonga, CA 91730, USA

<sup>b</sup> Department of Oral & Maxillofacial Surgery, Loma Linda University, 11234 Anderson Street, Loma Linda, CA 92354, USA

\* Inland Cosmetic Surgery, 8680 Monroe Court, Suite #200, Rancho Cucamonga, CA 91730.

E-mail address: [Jhaiavy@yahoo.com](mailto:Jhaiavy@yahoo.com)

concentrated in the upper face and periocular region, which was not addressed in the primary surgery (**Fig. 1**). During the secondary facelift, the surgeon can and should address those areas to achieve the best possible result.

Generally, most of the patients seeking a secondary procedure have their skin envelope tightened with the primary procedure, and therefore, little skin needs to be removed in the secondary procedure. On the other hand, their superficial musculoaponeurotic system (SMAS) and the muscles in the neck are commonly lax compared with the tightened skin envelope.<sup>3,4</sup> In recent years, the popularity of various forms of short-scar facelifts has given rise to an increasing number of patients with this presentation.

Because most of the primary facelifts performed do not involve an extensive sub-SMAS dissection, the secondary facelift will benefit from some form of SMAS undermining and tightening. The subcutaneous layer, which is the most common plane of dissection in a facelift, may be thinner after the trauma of the original procedure and facial fat atrophy,<sup>5</sup> creating a challenge in a thin patient. In those cases, it may be more prudent to perform an SMASectomy with plication rather than an SMAS elevation.

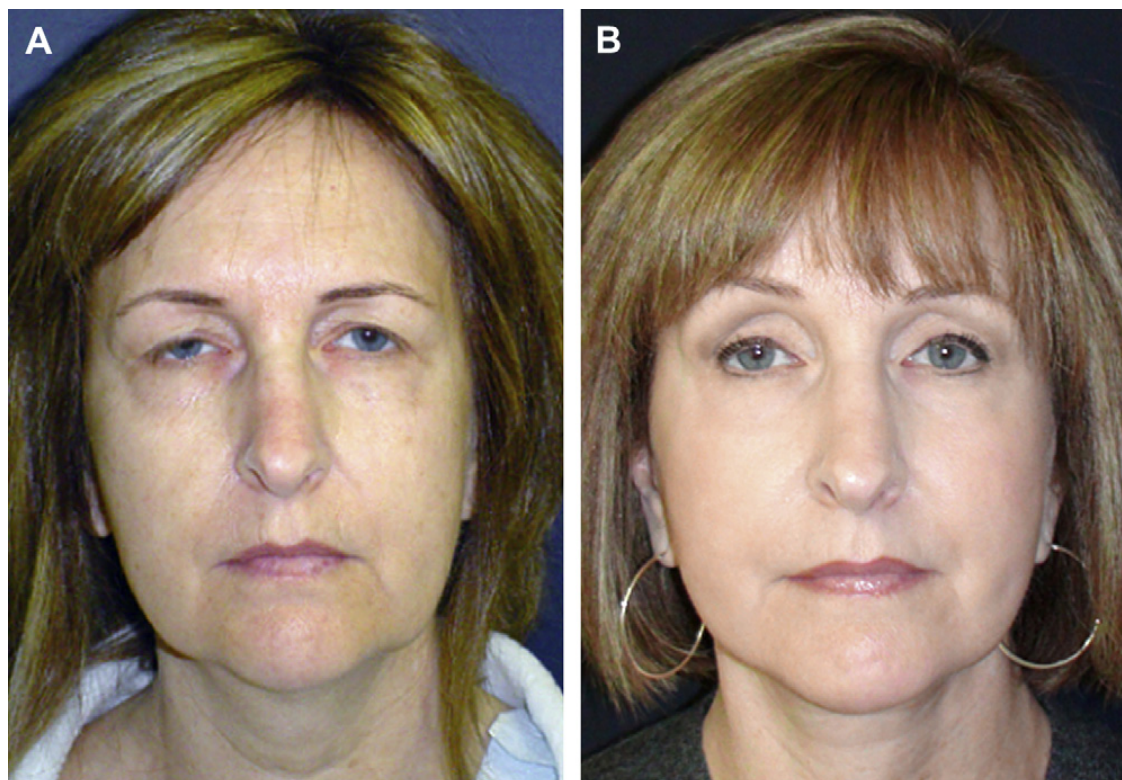
### INCISIONS AND SCARS

Incision placement during the secondary procedure is largely dictated by the incision line that

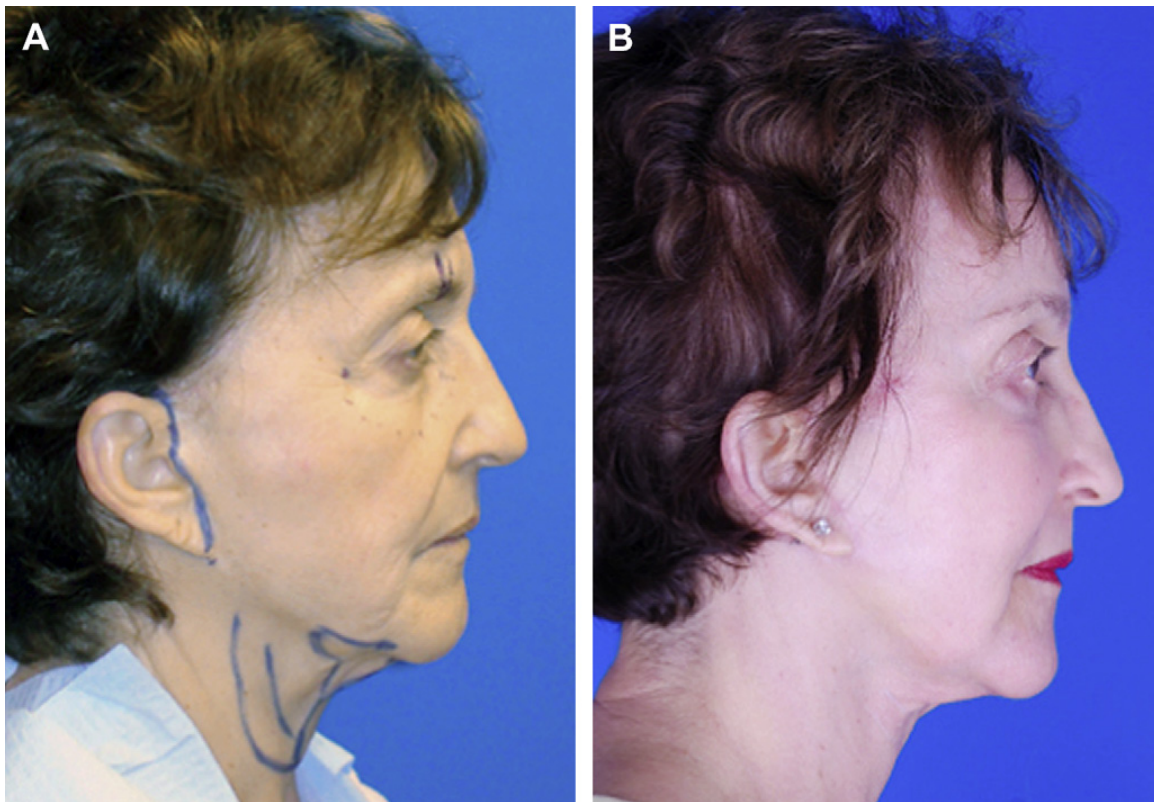was made during the first operation. The author's preference is to make a tragal margin incision or a retrotragal incision because it is easier to hide the scar and the scar heals well. Before making the incision, careful assessment of the amount of skin laxity present should be made, and if enough laxity is present, a preauricular incision can be converted to a tragal or retrotragal incision during the reoperation (**Fig. 2**). On closure of the flap, there should be minimal tension on the tragus. To minimize tension, the skin flap is sutured above and below the tragus with 4-0 Monocryl sutures.

### EARLOBE DEFORMITY

Another common stigmata of facelifts is the "bat ear" or "pixie ear" deformity (**Fig. 3A**). This deformity is a result of poor incision placement and excess skin removal caudal to the ear lobe during closure of the primary procedure. The closure of the earlobe cannot be under tension. The deeper structures of the jaw line and neck should be secured to a stable structure such as the postauricular fascia or the mastoid fascia, and the skin should be closed passively around the earlobe. To correct this deformity, the surgeon should incise the earlobe to a more rounded appearance and then inset the earlobe to its proper position, which is 10° to 20° posterior to the axis of the pinna (see **Fig. 3B**).<sup>6</sup> One should never attempt



**Fig. 1.** (A) A 62-year-old woman 10 years after her primary facelift complaining of recurrent sagging in the face and jowls. (B) Same patient 3 months after facelift revision, endoscopic brow lift, and full-face CO<sub>2</sub> laser resurfacing.



**Fig. 2.** (A) Preoperative markings of a 65-year-old woman 8 years after her primary facelift demonstrating a tragal margin incision. (B) Same patient 3 months after revisional facelift and neck lift with fat transfer to lower eyelids and a full-face trichloroacetic acid peel.

to hang the cheek on the earlobe during flap re-draping. Instead, the skin flap should be secured to the base of the ear lobe with a 3-0 Monocryl or 3-0 Vicryl suture. The skin of the earlobe is then closed with a 5-0 plain catgut suture under minimal tension (see **Fig. 3C**).

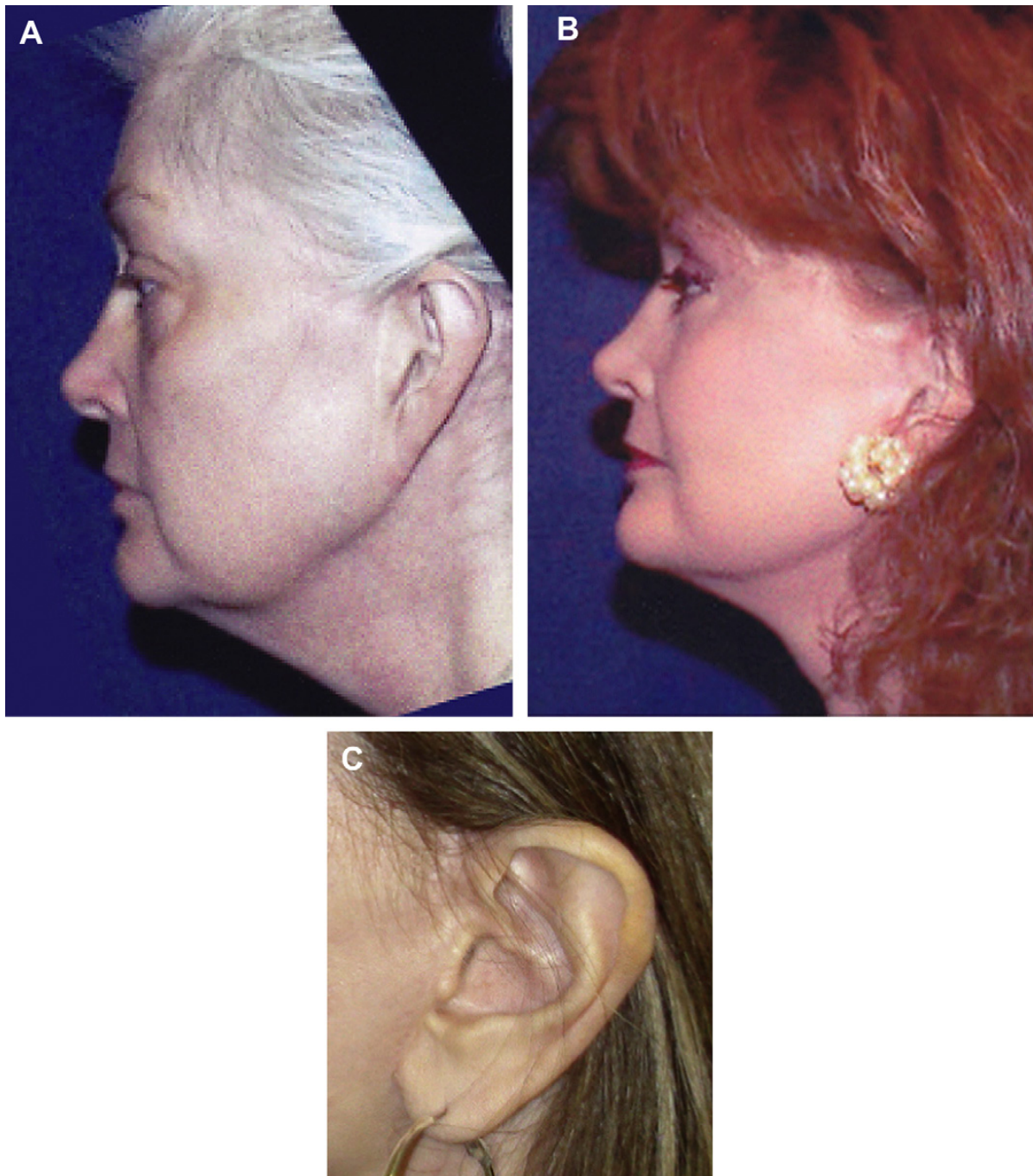### HAIR PATTERN CHANGES

One of the greatest challenges with incision placement in revisional facelift or neck lift is problems with hairline shifting and bald spots from the primary operation. Another common stigma of facelifts is distortion or the loss of sideburn and temporal hairline. This problem can occur when the cervicofacial flap is advanced too far in the cephalad direction, causing the hairline shift. For example, transposition of the sideburn above the helical rim can leave a bald spot above the ear. This problem is difficult to correct. It is occasionally possible to rotate the temporal hairline inferiorly and partially lower the sideburn. As is commonly the case, avoidance of this problem is the best course of action.

The author prefers to make the temporal incision in the hairline at the initial procedure and leave the sideburn or 1 cm of hair-bearing skin attached at the base of the helix. This method avoids improper transposition of hair in the temporal region. If skin

needs to be removed at that location, it is done in a conservative fashion, bearing in mind not to shift the temporal hairline. Another alternative for correction of this problem is to place the incision along the temporal hairline in the secondary procedure and avoid any additional hairline shifting at the time of flap advancement.<sup>1</sup>

In the postauricular region, there is a potential for visible scars when the incision in the primary procedure was made along the posterior scalp hairline. This scar can become wide and more visible when the neck tissues are suspended to the postauricular scalp skin as opposed to the deeper scalp structures. In the revisional procedure, the surgeon has the opportunity to remove some or the entire scar as long as enough laxity is present. It is the author's preference to make the new incision in the hairline cephalad to the old scar in a line that is perpendicular to the vector of pull. If the incision is made in a beveled manner and the dissection is made in a plane to avoid damage to the hair follicles, this incision heals so well that it is almost invisible a year later when the hairs have grown into the scar. When advancing the posterior cervical skin flap in a cephalic direction, the author places 1 or 2 deep permanent sutures (2-0 Ethibond or Nurolon [Ethicon, San Angelo, TX, USA]) that secure the deep portion of the skin flap to the deep posterior



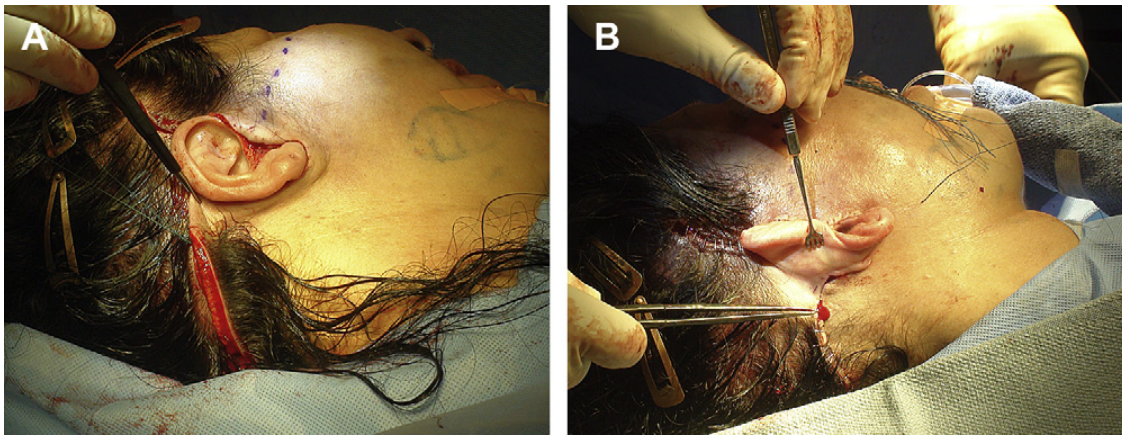
**Fig. 3.** (A) A 62-year-old woman 10 years after her primary facelift, with a visible preauricular scar and pixie ear deformity. (B) Same patient after secondary facelift with revision of preauricular scar, conversion to a tragal margin scar, and correction of pixie ear. (C) Close-up of a corrected earlobe with a previous pixie deformity.

scalp fascia and/or the periosteum (**Fig. 4A**). The excess skin and the old scar are then trimmed, and the incision is closed with staples passively under no tension. Care is taken to align the posterior hairline during closure (see **Fig. 4B**).

#### FAT IRREGULARITIES AND DEFICIENCIES

Because patients continue to age after their primary surgery, there is continued laxity of the skin and underlying tissues and facial fat atrophy. In addition, because patients are seeking these

procedures at an early age and have minimal neck laxity, surgeons have become more aggressive with cervical and facial fat removal. This situation had led to the problem of the patients presenting for a secondary procedure with an overskeletonized neck and submalar hollowing (**Fig. 5A**). This lack of subcutaneous fat makes it difficult to disguise the fascial and platysmal irregularities that may occur during surgical manipulation, especially on a thin patient. To correct this problem, in the secondary procedure instead of removing fat, the surgeon should attempt



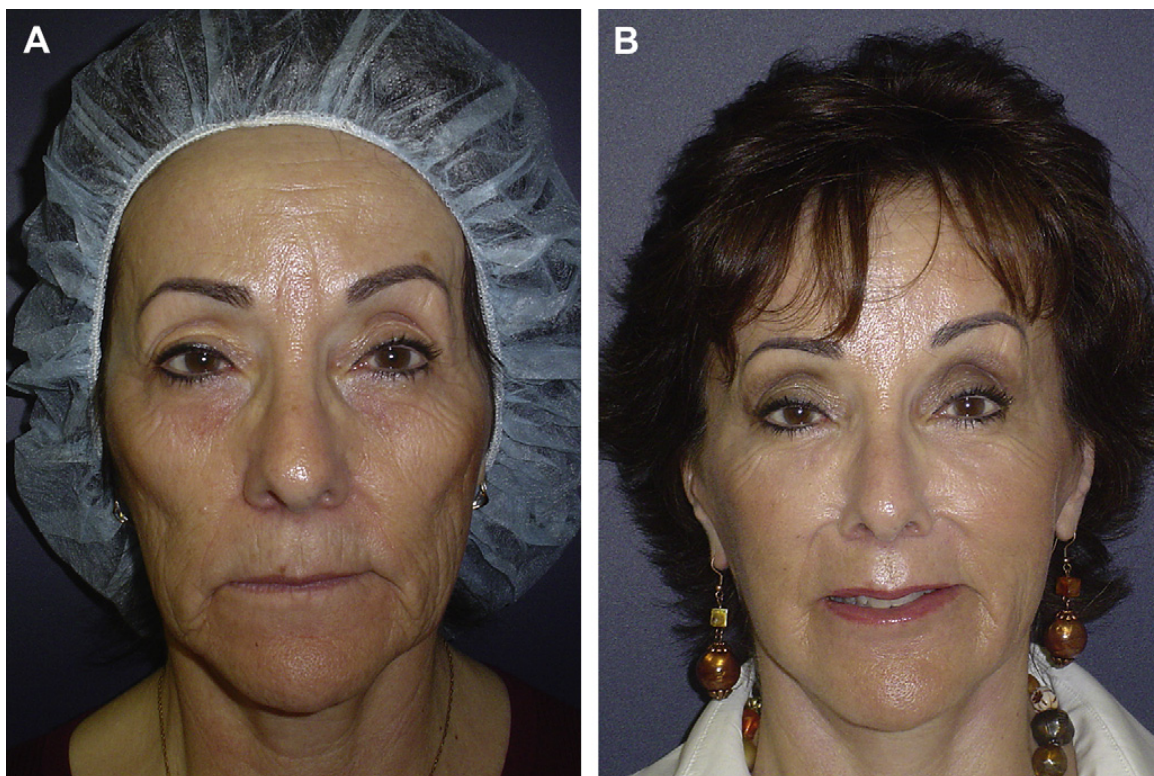**Fig. 4.** (A) Advancement and fixation of posterior cervical skin flap. Note the alignment of hair. (B) Closure and alignment of temporal and posterior scalp hairline.

redraping the patient's existing fat from the jowls cephalically over the buccal recess. In the author's practice, it has been more common to perform fat grafting than fat removal procedures during facelift revisions. Fat grafting can correct the hollowing in the submalar, infraorbital, and perioral regions (see **Fig. 5B**). Patients need to understand that they may need multiple fat grafting sessions to achieve the optimal results. With the advancements in stem cell research and isolation of stem cell from adipose tissue, it may not be long before revisional surgery can be combined with one session of stem

cell-enriched fat grafting to correct these problems.

#### FASCIAL LAXITY

Patients presenting for a secondary facelift or neck lift usually have minimal skin laxity, but more commonly they have some form of laxity in the deeper layers (SMAS and platysma muscle) that can lead to deepening of nasolabial folds, jowls, and platysmal banding. Usually, SMAS elevation is limited during the primary procedure. Therefore,



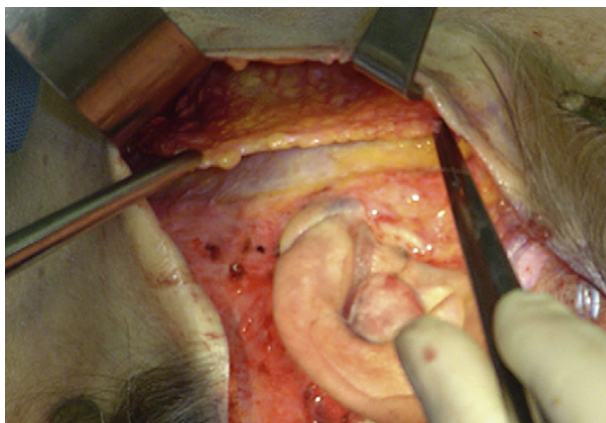
**Fig. 5.** (A) A 62-year-old woman demonstrating infraorbital, submalar, and cervical hollowing caused by fat atrophy after the primary procedure. (B) Same patient after reoperative facelift, endoscopic brow lift, and fat transfer to the eyes, cheeks, and lips, with full-face CO<sub>2</sub> laser resurfacing.

most patients benefit from reelevation and tightening of the deeper fascial layers (**Fig. 6**).<sup>1,7</sup>

The surgeon should be cautious because scarring from previous surgery can distort the anatomy. Fortunately, the scarring is mostly over the parotid gland, where the facial nerve branches are deep to the plane of dissection. It is also important not to carry the dissection too deep over the parotid, as damage to the gland can lead to a sialocele. Once the SMAS is freed past the parotid gland, the dissection becomes easier in the sub-SMAS areolar plane. It is important to understand the anatomy and relationship of the facial nerve to the SMAS and facial muscles (**Fig. 7**). The zygomaticus major and zygomaticus minor as well as orbicularis oculi and platysma muscles receive their innervations through their deep surface, whereas the buccinator, levator anguli oris, and mentalis muscles are innervated along their superficial surface.<sup>6</sup> Therefore, when the SMAS elevation is performed, as long as the dissection is carried out along the superficial surface of the facial muscles, injury to the facial nerve is not likely. Furthermore, as mentioned earlier, the author's approach is opportunistic, and the dissection is carried out medially only to the point needed to achieve adequate release and correction. This approach varies with each patient. If extensive scarring is present to the point where the relationship between the superficial and deep fascial layers is obscured, a simple SMAS plication is preferable (**Fig. 8**). Also, if the SMAS is found to be very thin and attenuated, it becomes difficult to perform a smooth elevation of that layer because it may tear. Therefore, a simple plication in this case may serve the patient and the surgeon better.

### THE CERVICOMENTAL ANGLE AND PLATYSMA

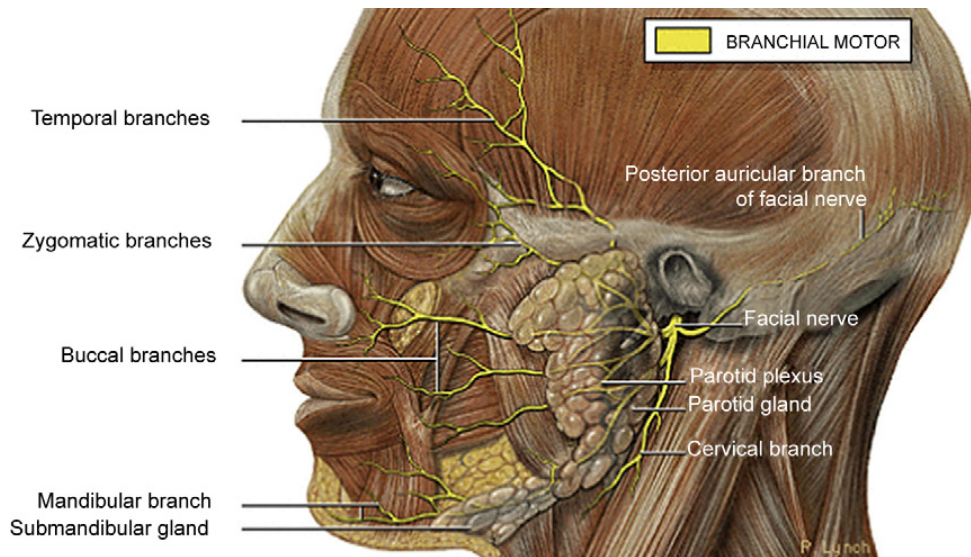
The cervicomental angle has been studied extensively. For ideal aesthetics, it should be



**Fig. 6.** Elevation of the deep layer and SMAS in a revisional facelift.

approximately 90°, but a wide range of normal neck morphology exists and the angle may vary from 105° to 120°.<sup>8,9</sup> The angle is usually more obtuse in women compared with men. A low and anteriorly positioned hyoid bone also leads to a more obtuse angle. This morphology can be camouflaged by placement of a chin implant to give the illusion of a more acute angle.<sup>10</sup> Because primary surgeries are being done at early ages, they usually involve removal of preplatysmal fat and tightening of cervical skin. With aging, the platysma muscle becomes more attenuated and the platysmal bands become more obvious. Another factor that can contribute to cervicomental obtuseness is fat accumulation under the platysma. In a revisional surgery, it is more common to see this condition than the accumulation of preplatysmal fat if the patient has gained significant weight. Therefore, in the revisional facelift or neck lift, every effort should be made to preserve the fat on the cervical skin flap, especially if subplatysmal fat removal is planned. The author does not routinely perform submental liposuction when performing a revisional neck lift, especially if an extensive platysmaplasty is planned.

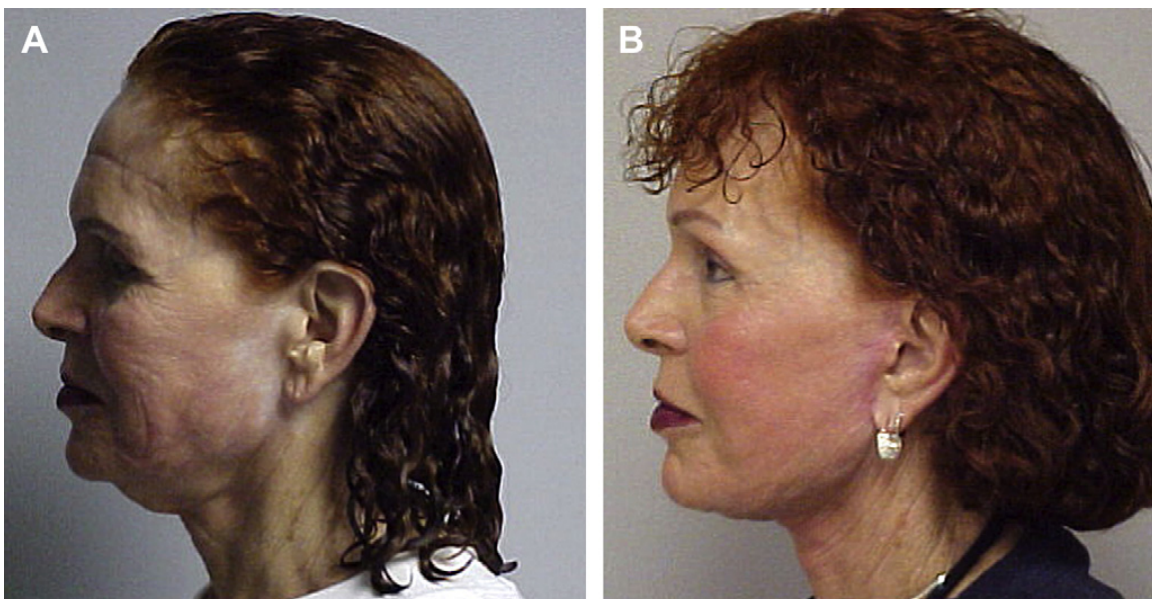The author's approach to the neck is through the submental incision centrally and the postauricular incision laterally. Once adequately exposed, the amount of platysmal laxity is evaluated, and if necessary, excess muscle and fat are clamped and removed centrally in a conservative fashion to prevent undue tension on the suture plication. The subplatysmal fat is then exposed by elevation of the medial borders of the platysma from the mentum to the level of the cricoid cartilage. The excess fat is then removed under direct vision with the Bovie cautery and scissors. Careful hemostasis must be obtained. This fat contouring has to be precise, and care should be taken to avoid overresection of fat in the submental region. This overresection can lead to a hollowed out submental appearance that is difficult to correct. A greater amount of fat can be removed at the level of the hyoid, where it helps to deepen the cervicomental angle. In addition, releasing the muscle laterally by performing a myotomy either at the level of the hyoid or just caudal to the last muscle plication suture relieves some of the tension along the platysmal plication and allows the platysma to shift superiorly, creating a deeper cervicomental angle (**Fig. 9**). This back cut or myotomy of the platysma is parallel to the inferior border of the mandible and away from the submandibular gland, facial artery, facial vein, and the facial nerve. After adequate mobilization of the platysma, the edges of the muscle are grasped and overlapped in the midline. Platysmal plication is then performed



**Fig. 7.** Relationship of the facial nerve to the facial muscles. (From Yale Center for Advanced Instructional Media, copyright 1998. All rights reserved; with permission.)

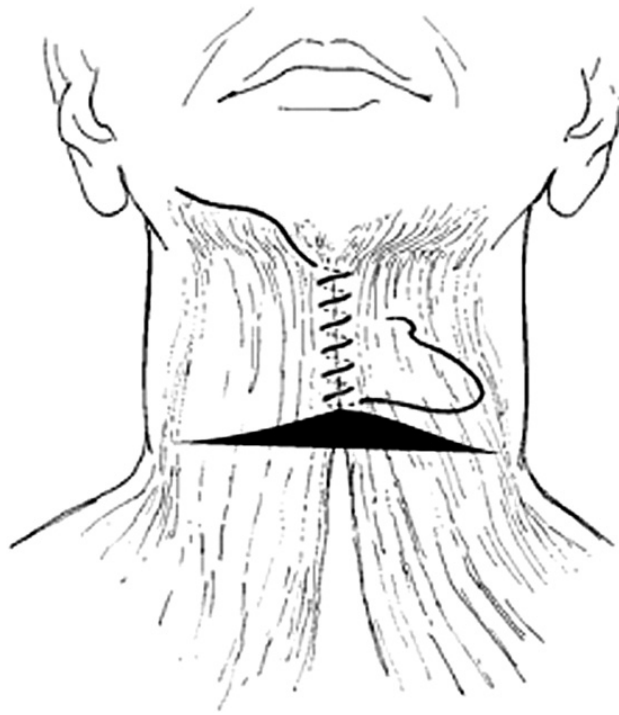
with interrupted 3-0 Vicryl or 3-0 silk sutures from the mentum to at least the level of the hyoid bone. The author often continues this plication lower to the level of the thyroid cartilage, especially on a long-necked person with long bands. In very thin patients with little subcutaneous fat, it is important to bury the knots and be careful to create a smooth contour because the anatomy created with the muscle plication is immediately visible under the skin with little padding. The goal of muscle plication is to produce an even smooth platysma contour that tightly adheres to the underlying structures, producing a proper framework for redraping of the cervical skin.

On occasion, patients presenting for secondary facelift or neck lift have bulging of their submandibular gland. This presentation can be secondary to overaggressive liposuction during the primary procedure or just ptosis of the gland with attenuation of the deep fascia and gland capsule. Some patients may accept this side effect of the primary procedure as an explanation of normal anatomy. During the secondary procedure, the surgeon can address the ptotic gland by either attempting a sling suture, such as the Giampapa suture from the submental region to each mastoid fascia, or performing partial resection of the submandibular gland. The gland can be approached through the



**Fig. 8.** (A) A 61-year-old woman 8 years after a subcutaneous facelift with extensive pre- and postauricular scarring. (B) Same patient after a revisional facelift with SMAS elevation and plication as well as endoscopic brow lift.





**Fig. 9.** Platysmal plication and lateral myotomy. (From Sykes JM. Rejuvenation of the aging neck. *Facial Plast Surg* 2001;17:103, Thieme-connect; with permission.)

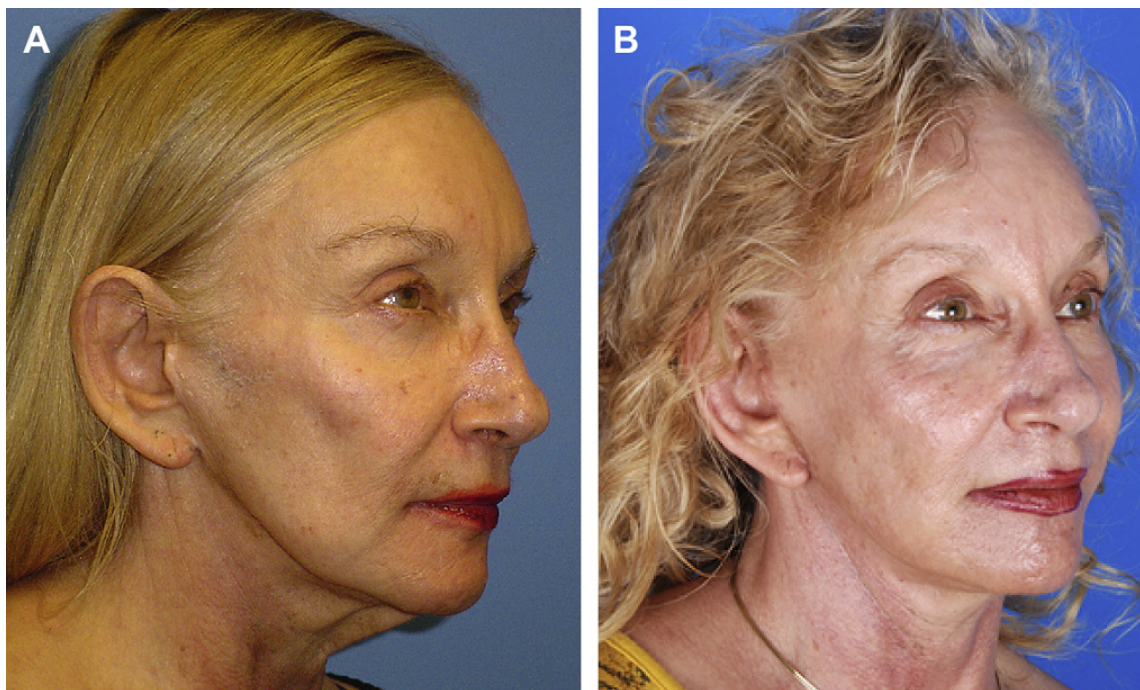subplatysmal dissection, whereby the cervical fascia is carefully penetrated over the bulge of the gland. The most inferior and anterior portion of the gland is then gently grasped, and the

excessive portion of the gland is removed. This procedure has to be done with extreme care and under excellent visualization because branches of the facial artery and vein and the mandibular branch of the facial nerve are close by and have to be preserved. This procedure should be reserved for the experienced surgeon who is very familiar with the anatomy.

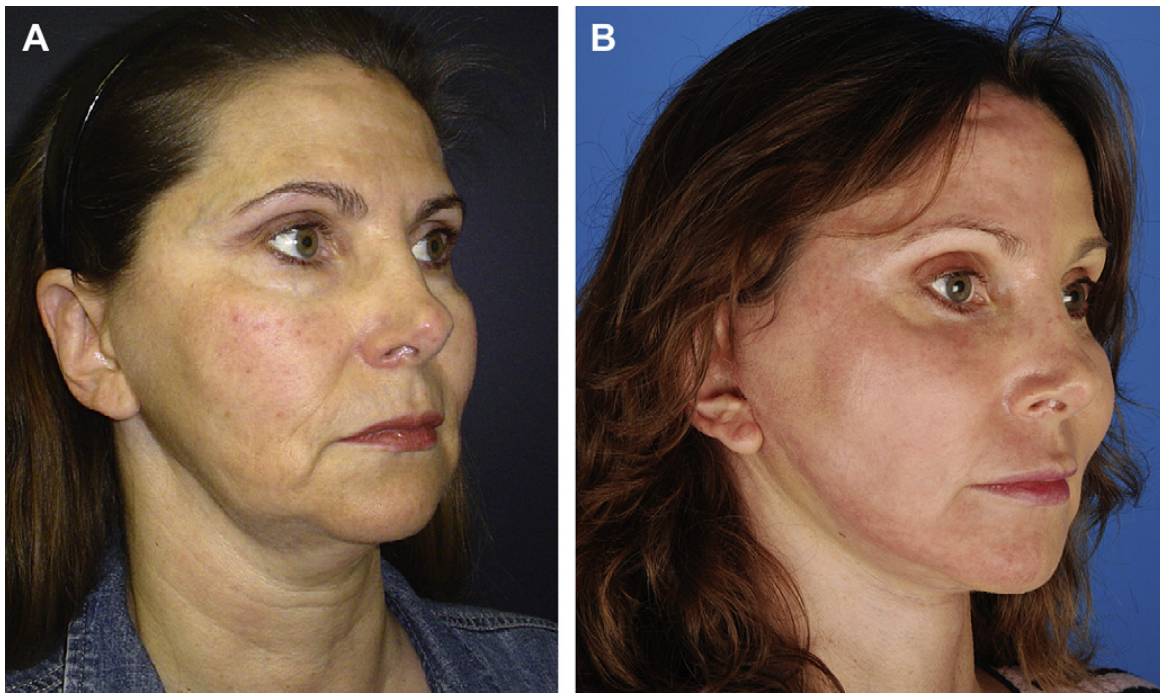
#### PRESENCE OF UNUSUAL RHYTIDS

Facial rhytids are not removed by facelifts or neck lifts, whether it is primary or revisional surgery. The rhytids are improved and redraped. Regarding nasolabial folds, Dr Howard Tobin (author's mentor) often calls them "undefeated nasolabial folds" and says, "nothing will remove them, but we can improve them." (Howard Tobin, MD, Abilene, TX, personal communication, 2000).

Occasionally, patients present for reoperation with unnatural-looking rhytids, which occur as a result of an exaggerated rotation of the cervico-facial flap, causing the rhytids to run in an upward direction. This condition is compounded by the fact that with aging, the patients lose some of the skin elasticity and have more actinic damage because of continued sun exposure, leading to inelastic poor-quality skin with keratotic changes and hyperpigmentation. Therefore, at the secondary procedure the surgeon should be aware of the direction of flap rotation to not



**Fig. 10.** (A) A 70-year-old woman 6 years after primary brow lift, facelift, upper and lower blepharoplasty, and cheek augmentation. (B) Same patient 6 months after revisional face and neck lifts and full-face trichloroacetic acid peel.



**Fig. 11.** (A) A 50-year-old woman 3 years after primary face and neck lifts. (B) Same patient 3 months after a facial tuck and full-face CO<sub>2</sub> laser resurfacing.

exaggerate the abnormal rhytids. Furthermore, laser skin resurfacing and/or chemical peels are useful adjuncts to the secondary procedure; these techniques can correct the actinic changes and improve some of the fine lines and rhytids (Fig. 10). When combining revisional surgery with laser resurfacing or chemical peeling, the skin dissection is kept to the minimum and the lift must rely mostly on the rotation of the deeper musculofascial structure. This method works well because most of the patients presenting for the secondary procedure have little skin laxity. On smokers, is advisable to do shorter skin flaps and rely mostly on the SMAS and platysma dissection. The skin flap in reoperations should be more resistant to vascular compromise, especially because it was delayed during the primary procedure.<sup>7</sup>

### FACE TUCK

A common question presented by patients is “How long will my facelift last?” A recent article tried to answer this question for a single surgeon.<sup>11</sup> The author’s standard answer is “The changes that one will make to your face are permanent but you will continue to age.” Patients who want to maintain their lifted appearance are better served with a face tuck within the first 2 to 3 years after the primary procedure (Fig. 11).

In that period, the scar tissue is still fairly resilient and the pull in the periauricular area can be easily transmitted to the jowl and neck. When the wait for

the secondary procedure is longer, a combination of skin elevation, SMAS dissection and plication, as well as platysmal manipulation followed by careful skin redraping often leads to considerable improvement and a satisfied patient.

### SUMMARY

The complexity of the revisional facelift or neck lift is directly related to the way the primary procedure was performed. With so many techniques now available to the facial cosmetic surgeon, such as the subcutaneous facelift,<sup>12</sup> variations of SMAS or extended SMAS procedures,<sup>13–15</sup> lateral SMASectomy,<sup>16</sup> deep plane and composite rhytidectomy,<sup>17,18</sup> subperiosteal facelift,<sup>19,20</sup> and short-scar facelifts,<sup>21</sup> the revisional procedure should be directed to the specific problems that the patient exhibits, such as laxity in the upper face, laxity in the neck, jowling, or deepening of the nasolabial folds. In general, it is more prudent to restore contour within the deep layer support by the elevation of the SMAS and platysma rather than by rotating skin flaps in an exaggerated manner in a cephalad direction producing a tight unnatural look. In addition, it is extremely important that the posterior hairline and the temporal hairline are correctly aligned at the time of closure.

### REFERENCES

1. Guyuron B. Secondary rhytidectomy. *Plast Reconstr Surg* 2004;114(3):797–800.

2. Tobin HA, Cuzalina A, Tharanon W, et al. The biplane facelift: an opportunistic approach. *J Oral Maxillofac Surg* 2000;58:76–85.
3. Mitz V, Peyronie M. The superficial musculo-aponeurotic system (SMAS) in the parotid and cheek area. *Plast Reconstr Surg* 1976;58:80.
4. Jost G, Levet Y. Parotid fascia and face lifting: a critical evaluation of the SMAS concept. *Plast Reconstr Surg* 1984;74:42–51.
5. Little JW. Applications of the classic dermal fat graft in primary and secondary facial rejuvenation. *Plast Reconstr Surg* 2002;109:788–804.
6. Stuzin MJ. Reoperations and refinements after rhytidectomy. In: Nahai F, editor. *The art of aesthetic surgery: principles and techniques*. St Louis (MO): QMP; 2005. p. 1286–326.
7. Guyuron B, Bokhari F, Thomas T. Secondary rhytidectomy. *Plast Reconstr Surg* 1997;100(5):1281–4.
8. Sarver MD, Proffit RW, Ackerman LJ. Evaluation of facial soft tissues. In: Rudolph P, Alvis K, editors. *Contemporary treatment of dentofacial deformities*. St Louis (MO): Mosby; 2003. p. 98–126.
9. Ellenbogen R, Karlin J. Visual criteria in restoring a youthful neck. *Plast Reconstr Surg* 1980;66:826–37.
10. Cuzalino A, Koehler J. Submentoplasty and facial liposuction. *Oral Maxillofac Surg Clin North Am* 2005;17(1):85–98.
11. Sundine JM, Kretsis V, Connell B. Longevity of SMAS facial rejuvenation and support. *Plast Reconstr Surg* 2010;126(1):229–39.
12. Duffy MJ, Friedland JA. The superficial-plane rhytidectomy revisited. *Plast Reconstr Surg* 1994;93:1392–403.
13. Connell BF, Semlacher RA. Contemporary deep layer facial rejuvenation. *Plast Reconstr Surg* 1997;100:1513–23.
14. Baker TJ, Stuzin JM. Personal technique of face lifting. *Plast Reconstr Surg* 1997;100:502–8.
15. Stuzin JM, Baker TJ, Gordon HL, et al. Extended SMAS dissection as an approach to midface rejuvenation. *Clin Plast Surg* 1995;22:295–311.
16. Baker DC. Lateral SMASectomy. *Plast Reconstr Surg* 1997;100:509–13.
17. Hamra ST. The deep-plane rhytidectomy. *Plast Reconstr Surg* 1990;86:53–9.
18. Hamra ST. Composite rhytidectomy. *Plast Reconstr Surg* 1992;90:1–13.
19. Ramirez OM, Maillard GF, Musolas A. The extended subperiosteal face lift: a definitive soft-tissue remodeling for facial rejuvenation. *Plast Reconstr Surg* 1991;88:227–36.
20. Tobin HA. The extended subperiosteal coronal lift. *Am J Cosmet Surg* 1993;10:47–57.
21. Tonnard P, Verpaele A. The MACS-lift short scar rhytidectomy. *Aesthetic Plast Surg* 2007;27:188–98.