

Transumbilical Breast Augmentation

A Practical Review of a Growing Technique

William A. Brennan, MD, and Jacob Haiavy, MD

Background: The transumbilical breast augmentation procedure has been described in the literature since 1993. This indirect route for implant placement has received both criticism and praise over the years, without a comprehensive assessment of the procedure from the perspective of the patient. The growing patient demand for the procedure, combined with the increased use by surgeons, prompts a review of the procedure and a discussion of its pros and cons, including tabulated patient satisfaction data.

Methods: A retrospective chart review of 245 transumbilical breast augmentations performed by the second author from 2002 to 2004, including the 1-year patient satisfaction surveys, is presented. Additionally, complications from the procedure are also tabulated and compared with the complications published by our studies' dominant implant manufacturer in their 1-year follow-up published data. The patients were asked to rate their postoperative pain, numbness, firmness, size satisfaction, rippling, and overall satisfaction. Data were compiled and statistical analysis was performed using χ^2 methods.

Results: The study revealed a strong negative correlation between both the study parameters of prepectoral implant location and postoperative firmness and the survey result of overall satisfaction ($P = 0.0041$). Conversely, numbness, pain, and rippling, long felt to be linked to satisfaction, were shown to have no statistical correlation with satisfaction. A strong positive correlation with satisfaction was seen with retropectoral (submuscular) implant location. The complications from transumbilical breast augmentation in our study were hematoma = 1 (0.4%), umbilical wound infection = 8 (3.2%), deflation = 3 (1.2%), tunnel seromas = 5 (2.0%), asymmetry = 10 (4.1%), capsular contracture = 9 (3.7%), implant infection (0.0%).

These complication rates were comparable or less than other published methods of breast prosthesis implantation.

Conclusions: Transumbilical breast augmentation is a safe and effective method for breast implant placement in selected patients. Patient satisfaction weighs heavily on implant location and postoperative firmness and less on other variables. The procedure is associated with a complication rate comparable with other methods and finds itself growing in demand and popularity secondary to high patient satisfaction.

Key Words: transumbilical breast augmentation, breast augmentation surveys, endoscopic breast surgery

(Ann Plast Surg 2007;59: 243–249)

Transumbilical breast augmentation (TUBA) was described during a time in the surgical sciences when the surgical endoscope was graduating from its use in gastrointestinal medicine towards its use in the operating room for other purposes.¹ This effort led to advances in every aspect of surgery, from the general surgeon's laparoscopic cholecystectomy to the neurosurgeon's endoscopic approach to the cranium. It is not surprising that this avenue of surgical guidance found application in the field of breast augmentation for 2 reasons: first because the acceptance of cosmetic procedures was integrated with the resultant location and size of the scar left behind by the procedure and second because this acceptance was also entwined with the mandatory downtime associated with the procedures. Endoscopic guidance had potential for reducing these concerns for the cosmetic patient.

According to national surveys, breast augmentation continues to grow in popularity and acceptance, alongside cosmetic procedures in general.^{2,3,11} Patients, as well as surgeons, have always expressed a desire to have breast augmentation follow a path of safety, efficiency, and cosmetic appeal. Since Johnson and Christ¹ published TUBA in 1993, the procedure has been accepted, criticized, disseminated, and occasionally modified in pursuit of this quest. Dowden^{4,5} and Caleel⁶ have contributed to the literature in multiple publications describing the TUBA procedure and have described the procedures limitations, as well as advantages. This author expects that as this technique becomes more widespread in use, more surgeons will benefit from having practical clinical publications from which to draw their own conclusions. This publication will present the corresponding authors' chart review of practice data from

Received September 13, 2006, and accepted for publication, after revision, November 28, 2006.

From *Surgical Arts of Beverly Hills, Inc., Beverly Hills, California, and †Inland Cosmetic Surgery, Rancho Cucamonga, California.

The preliminary data from this study have been presented at the American Academy of Cosmetic Surgery Annual Meeting, Orlando, Florida, January 2006.

Financial Disclosure and Products: Neither William A. Brennan, MD, nor Jacob Haiavy, MD, has any financial interest in the manufacturers or products mentioned in this manuscript. This manuscript was prepared without outside support from any corporate sponsor or affiliation.

Reprints: William A. Brennan, MD, Surgical Arts of Beverly Hills, Inc., 9401 Wilshire Blvd., Suite 1105, Beverly Hills, CA 90212. E-mail: Wab90210@aol.com.

Copyright © 2007 by Lippincott Williams & Wilkins

ISSN: 0148-7043/07/5903-0243

DOI: 10.1097/SAP.0b013e318030264f

January 2002 to June 2004, wherein the TUBA procedure was performed. Patient surveys were used in the generation of follow-up information.

MATERIALS AND METHODS

All patients were seen in consultation in the office and assessed for their candidacy for breast augmentation. All patients had a detailed discussion of risks, benefits, and alternatives to surgery. All patients had alternate implant insertion techniques described and discussed. Patients were excluded if they had extensive abdominal procedures in the past, with scarring, severe flair rib, or significant chest-wall deformity or tuberous breast anatomy. Detailed medical history, physical examinations, breast measurements, and appropriate laboratory data were obtained. All patients were given home sizing tasks to determine the optimal size for themselves. This exercise involved using a home measurement system that allowed the patients to create filling material for their undergarment which gave them the most appealing size. Mammograms were recommended on women age 35 and over or with a family history of breast cancer. During the initial consultation, standard breast measurements⁷ were taken, and the information was used to craft recommendations to the patient regarding the appropriateness of the procedure itself, as well as explaining criteria for making the implant location decision. Patients who had breast thickness measurements of 3 cm or greater were given the option of having their implants in either the prepectoral or retropectoral location. Patients who had small rib-cage anatomy generally had high-profile implants recommended to avoid excessive projection in the lateral direction. The patients were seen the morning of surgery, preoperative photos taken, preoperative markings performed, preoperative checklists completed, and the patients were then escorted to the surgery center. Anesthesia for all patients was general, with the majority utilizing a laryngeal mask airway device with an anesthesiologist or nurse anesthetist. All but a few surgeries were performed as an outpatient in an Accreditation Association for Ambulatory Health Care, Inc. accredited Ambulatory Surgery Center. A few select patients' surgeries were performed at a local hospital. All patients were seen in follow-up in 1 day, 1 week, 6 weeks, and 3 months postoperative and surveys completed by filling out the questionnaire on a 1-year follow-up visit. Patients who did not present for their scheduled 1-year follow-up appointment were sent survey forms. The surgical staff completed the survey form by telephone at 1 year with those patients who did not return forms and could be reached by a single telephone call. Out of the original 484 patients, 245 achieved completed survey forms (50.6%) via the above method. Patients with special needs were seen more frequently. Postoperative photographs were taken on the patients' last office visit before discharge at 3 months postoperative.

Age of the patients ranged from 18 to 64 years old, with a mean of 31.4 years old. The implant types involved in the study were McGhan (Style 68) round smooth saline (159), McGhan (Style 68HP) round smooth saline high profile (68), and Mentor (Style 3000) round smooth saline (18). The

parameters tabulated in our study were age, implant size, implant location (retropectoral or prepectoral), implant volume, overfilling volume, operating room time, development of complications, and complications requiring reoperation. The questions asked of the patients on the survey forms 1 year after surgery were breast pain, sensory disturbance and percentage change from preoperative sensation, development of firmness, degree of rippling, satisfaction with size, as well as overall satisfaction. A scoring system was devised to digitize each parameter on the patient survey. Breast pain was scored in a way that each breast could be assessed separately. A numeric score of 0-3 was given to each level of pain on the breast (0 = no pain, 1 = mild pain, 2 = moderate pain, 3 = severe pain). A score of 0.5 was given if the patient's reported pain was unilateral. Sensory disturbances were categorized as hypoesthesia or hypesthesia or no change based on the patient's response. A score of 0.5 was given to each breast, resulting in a range of -1.0 (bilateral hypoesthesia) to +1.0 (bilateral hypesthesia) and "0" being no change in sensation. Firmness was scored by using a modified Baker classification system subjectively in the survey and allowing the patient to choose from one of 4 categories, (1) no firmness present, (1.5) one breast is firm but not objectionable, (2) both breasts are firm but not objectionable, (2.5) one breast is firm but not uncomfortable, (3) both breasts are firm but not uncomfortable, (3.5) one breast is firm and uncomfortable, with pain, and (4.0) both breasts are firm and uncomfortable, with pain. Only capsular contractures of Baker classification 3 and 4 are included as complications. Rippling was scored by asking the patient if they had rippling that was visible (V) or palpable only (P). Patient size satisfaction was scored according to their response of "yes" if they were satisfied with their size or "no" if they wished they had chosen larger or smaller implants. Overall satisfaction was scored according to the scale (0) not satisfied, (1) fairly satisfied, (2) satisfied, or (3) very satisfied. Complications were tabulated and reported. Causes for reoperation are tabulated and reported.

RESULTS

The average implant size in our study was 455.5 mL (range, 225 mL to 800 mL). The average overfill volume was 34 mL (range, 0 mL to 100 mL). The average operating room time was 43.9 minutes (24-136 minutes). The locations were 208 retropectoral (84.9%) and 37 prepectoral (15.1%). The breast 1-year scores and corresponding percentages are presented in Table 1. Complications were tabulated and are presented in Table 2. Out of 245 patients, 1 patient (0.4%) had a hematoma; 8 patients (3.2%) had local wound infections at the umbilicus. No implant infections were seen in our study. All patients with localized umbilical incision infections were treated with oral antibiotics, and 1 patient (0.4%) had incision and drainage of a periumbilical abscess. Deflation of the implants occurred in 2 patients (0.8%). Seromas arising from the transumbilical dissection tunnel, seen more often in thin patients, were seen in 5 patients (2.0%) and resolved spontaneously with only compressive garments for 2 weeks in all but 2 patients (0.8%), who required one-time needle aspiration in the office. Postoperative asymmetry was

TABLE 1. Postoperative Patient Survey Scored Results at 1 Year

Pain Scale 0.0–3.0		Sensory Disturbance Scale –1.0 to +1.0		Firmness Scale 1–4		Rippling	
0.0	217 (88.5%)	+1.0	22 (9.0%)	1	209 (85.3%)	None	126 (51.4%)
0.5	11 (4.5%)	+0.5	2 (0.8%)	1.5	2 (0.8%)		
1.0	10 (4.0%)	0	142 (58.0%)	2.0	24 (5.3%)	Palpable	28 (11.4%)
1.5	5 (2.0%)	–0.5	27 (11.0%)	2.5	1 (0.4%)		
2.0	1 (0.4%)	–1.0	52 (21.2%)	3.0	5 (2.0%)	Visible	91 (37.1%)
2.5	1 (0.4%)			3.5	1 (0.4%)		
3.0	0			4.0	3 (1.2%)		

Pain scale 0–3: 0 = no pain, 1 = mild pain, 2 = moderate pain, 3 = severe pain. Sensory scale –1.0 to +1.0: 1.0 = bilateral hypoesthesia, +1.0 = bilateral hyperesthesia. Firmness scale 1–4: 1 = no firmness, 2 = firm but not objectionable, 3 = firm but not uncomfortable, 4 = firm and uncomfortable (0.5 units = unilateral).

TABLE 2. Complications and Reoperation Data at 1 Year From 245 Patients in the Transumbilical Breast Augmentation Study

Complications		Reoperations	
Hematoma	1 (0.4%)	Umbilical infection	1 (0.4%)
Umbilical infection	8 (3.2%)	Deflation	3 (1.2%)
Deflation	3 (1.2%)	Asymmetry	3 (1.2%)
Tunnel seromas	5 (2.0%)	Capsular contracture	5 (2.0%)
Asymmetry	10 (4.1%)	Overall	12 (4.8%)
Capsular contraction	9 (3.7%)		
Implant infection	0 (0.0%)		

seen in 10 patients (4.1%). Capsular contracture Baker grade III or IV was seen in 9 patients (3.7%). Zafirlukast (Accolate) (Astra Zeneca Pharmaceuticals, Wilmington, DE) 20 mg twice daily was given orally in all of these capsular contracture patients⁸ after obtaining and reviewing the patients' liver profile. Four of the 9 patients (44.4%) responded and avoided surgical treatment. The remaining 5 patients required surgical treatment. Reoperation within the 1-year survey occurred in 12 patients (4.9%), and the reasons for the reoperation are seen in Table 2. There were no instances of implant trauma or rupture. Separate sizers were used for pocket expansion. Satisfaction data were analyzed and tabulated in Table 3.

The results were given to our statistician, and the data were analyzed via χ^2 techniques to determine whether significant data sets correlated. We were primarily interested in which survey parameters correlated with patient satisfaction in a statistically significant manner. We found that no correlation ($P > 0.05$) between the parameters of patient age,

operating room time, implant size, overfill volume, and implant type on patient satisfaction. Of interest in this study is that in the 1-year patient follow-up survey results, pain, numbness, and rippling did not correlate with patient satisfaction. The 1-year follow-up survey result that did show a positive correlation with patient satisfaction was a retropectoral implant location ($P = 0.0097$). A solid negative correlation was seen with prepectoral implant location ($P = 0.0097$) and patient perceived firmness ($P < 0.0001$). These results are shown in Table 4.

The results of our study were then compared with the published information regarding postoperative complications by the predominant implant manufacturer⁹ (Inamed Corp, Santa Barbara, CA) in our study. The 1-year follow-up complications data are compiled and presented in Figure 1. Composite before-and-after photographs on 2 typical patients are presented in Figure 2.

DISCUSSION

Breast augmentation is a procedure that has gone through many changes since it was first introduced in the late 1960s. The procedure, as well as the implants themselves, has been the subject of much public attention and governmental regulation. Most of the focus of the attention has been on the implants as they have gone through modifications. The technique for implantation will likely continue along a similar path. Several articles in the surgical literature have described the TUBA technique in detail.^{1,4–6,10} The main purpose of this presentation is to review the results of one of the latest technique modifications in breast augmentations and to focus

TABLE 3. Patient Satisfaction at 1 Year From 245 Patients in the Transumbilical Breast Augmentation Study

Size Satisfaction at 1 Year		Surgery Satisfaction at 1 Year	
Wish bigger	27 (11.0%)	Not satisfied	2 (0.8%)
		Fairly satisfied	8 (3.3%)
Wish smaller	6 (2.44%)	Satisfied	40 (16.4%)
		Very satisfied	194 (79.5%)
Size OK	212 (86.5%)	Overall satisfaction (satisfied + very satisfied)	234 (95.9%)

TABLE 4. Statistical Correlation Data From 245 Patients in the Transumbilical Breast Augmentation Study: "Pain, Numbness, Rippling, and Firmness" as They Were Reported in the 1-Year Patient Surveys

No Correlation		Correlations	
Age	<i>P</i> = 0.3683	Positive	
Implant volume	<i>P</i> = 0.4009	Retropectoral Location	<i>P</i> = 0.0097
Overfill volume	<i>P</i> = 0.7637	Negative	
OR time	<i>P</i> = 0.7245	Prepectoral location	<i>P</i> = 0.0097
Pain	<i>P</i> = 0.1234	Firmness	<i>P</i> = 0.0041
Numbness	<i>P</i> = 0.1229	Capsular contracture	<i>P</i> = 0.0054
Rippling	<i>P</i> = 0.7012	Any complication	<i>P</i> = 0.0002
Asymmetry	<i>P</i> = 0.3916		

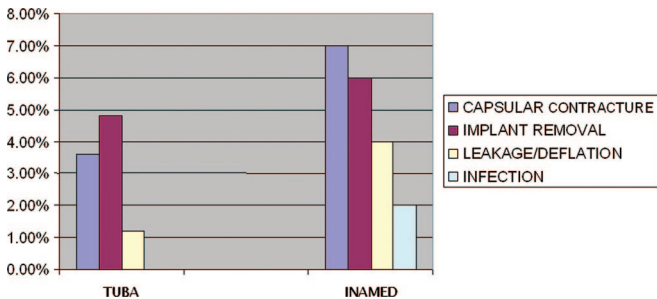


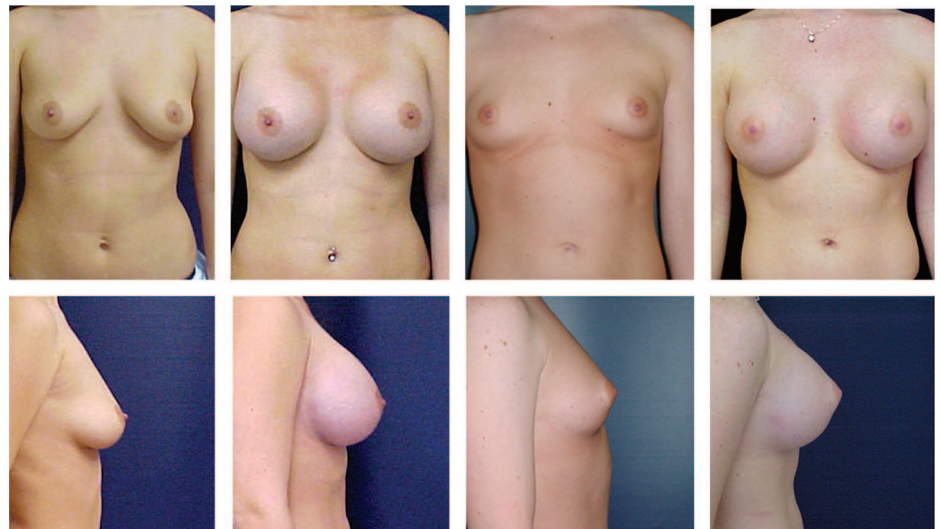
FIGURE 1. Graphic comparison of the 1-year complication percentages from the 245 transumbilical breast augmentation (TUBA) patients in the survey group to published 1-year complication percentages provided by the predominant implant manufacturer in our study (Inamed Esthetics, Santa Barbara, CA). Implant removal was tabulated as a percentage of the patients in the study who underwent reoperation for any indication.

on the procedure from a practical clinical perspective. Although the presentation tabulates data based on patient surveys, which are inherently subjective, it draws attention to the results of the procedure from the patient’s viewpoint. One of the principal advantages of the transumbilical approach from

the patient’s perspective is the displacement of the surgical incision from the breast, or immediately adjacent areas, to a less conspicuous location. Dowden⁵ has written that a week-long training course in TUBA, including a cadaveric workshop, should suffice in obtaining the necessary skills for proceeding towards offering the procedure to patients. All surgeons who have taken similar courses will agree that a learning curve exists in every procedure, and we would offer that TUBA is no exception. We would also agree with Dowden⁵ about informing the patient that an alternative incision may need to be used if there is unforeseen difficulty placing the implants with this technique. Even in the most experienced hands, an alternate incision may need to be used, especially in the surgeon’s first year of offering this procedure, and subsequently this option should be discussed but rarely used.

Controlling bleeding during this procedure has not been problematic due to 2 principal advantages: the blunt dissection inherent to the procedure, combined with the tumescent infiltration used along the dissection path. A significant amount of dissection is done with the saline infused sizers. This aspect makes subpectoral dissection less problematic once the initial correct tissue plane has been entered with the long blunt instruments.

FIGURE 2. Preoperative and 90-day postoperative photographs on typical patients in our transumbilical breast augmentation study. Case 1: A 24-year-old WF G₁P₁ who underwent retropectoral placement of 480-mL saline implants filled to 510 mL bilaterally. Case 2: A 22-year-old WF G₀P₀ who underwent retropectoral placement of 425-mL saline implants filled to 435 mL on the right and 450 mL on the left. Above, frontal views of the 2 patients (G₁P₁ patient on the left) with preoperative view on the left and postoperative view on the right. Below, lateral views.



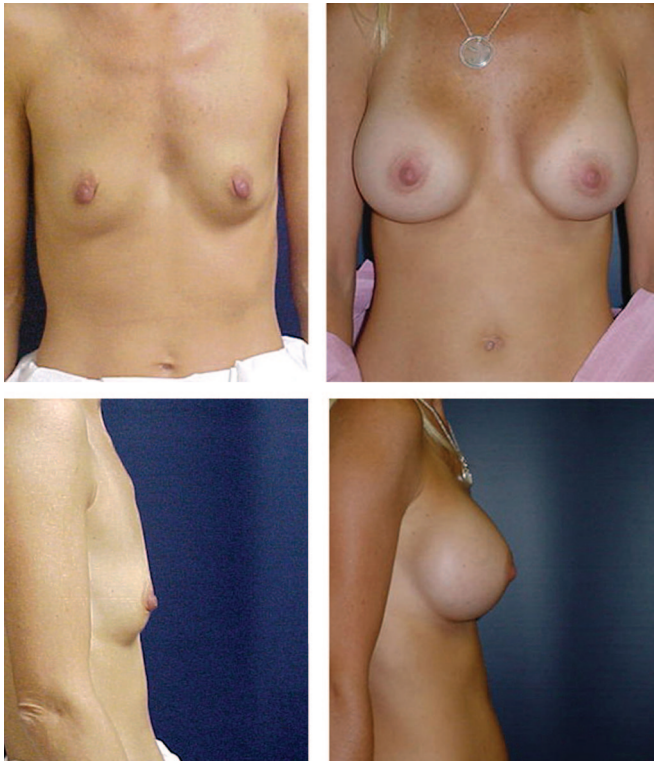


FIGURE 3. Preoperative and 90 days postoperative photos of a 38-year-old WF mother of 4 who desired 400-mL saline implants through a transumbilical retropectoral route. The inframammary to nipple distance measurements required a fold lowering of 1.5 cm. Left, above and below, preoperative photos in the frontal and lateral position respectively. Right, above and below, ninety-day postoperative photos in the frontal and lateral position respectively. The inframammary fold can be seen to be lowered to fit the 400-mL saline implant which were filled to 420 mL on the right and 430 mL on the left.

Although the data presented indicate a small percentage of wound infections at the umbilical site, there were no infections of the implants themselves, and the majority of these patients had oral antibiotics as their only treatment. The distance from incision to implant is believed to contribute to the zero incidence of implant infection in our study. Other surgical specialties have researched the effect of operating room time on implant infection and have found a direct correlation.¹¹ This average operating room time of 44 minutes stands well in comparison to other techniques for implantation of breast prostheses.

The sensory disturbance reported here shows that the majority of patients can expect no change in their nipple sensation; however, all patients should be told they can expect disturbance of breast, areolar, and nipple sensation as a result of this procedure and that this disturbance should improve with time after the procedure. In some rare cases, sensory disturbance may be permanent. These surveys asked patients about sensory loss to any degree anywhere in the chest area. Our experience had been that the TUBA procedure usually results in sensory disturbance at the inferior pole

of the breast and rarely involves the nipple-areolar complex. Okwueze et al¹² described a Vanderbilt study that used the pressure-specified sensory device in assessing postoperative sensory disturbance after breast augmentation using periareolar and other techniques. That study also compared this to postoperative questionnaires. They found significant sensory disturbance (67%-71%) in nipple/breast sensation according to questionnaires of patients 6 months postoperatively. However, quantitative measurements performed with measuring equipment that could be standardized from patient to patient revealed much less significant sensory changes. Further surveys in our practice may recruit such measuring devices, and questionnaires will be modified to allow more quantitative entries by patients. Surprisingly, the sensory data showed no correlation to patient satisfaction. This confirms the data presented by Okwueze et al¹² that only 12% of patients would reconsider surgery if they knew they would have sensory changes in the nipple/breast area.

Capsular contracture has been reported to be associated with postoperative hemorrhage, infection, and revision augmentation.^{13,14} The capsular contracture rate reported here compares well with that of the implant manufacturer and other published studies involving alternative incisions and dissection techniques.⁸ There does not appear to be any validity to notions that the TUBA procedure either leads to more bleeding or direct trauma of the implant. Our observation has been that the transumbilical approach actually has less bleeding than other techniques due to the absence of sharp dissection under the breast. Given the relationship between implant infection and capsular contracture, the transumbilical route has the advantage of less implant infections and hence less preponderance for capsular contracture. The technique resulted in no implant ruptures due to trauma to the implant. Deflations in this study were either below or comparable to previous reports associated with other techniques.¹³

These data represent TUBA procedures overwhelmingly performed retropectorally. Surgeons have been reluctant to use this technique retropectorally because of concern regarding the safety of elevating the pectoralis major off the chest wall. With proper infiltration of tumescent fluid and meticulous technique, retropectoral TUBA is not only possible but preferred in our patient population. Patients undergoing this procedure appear to have less postoperative pain than other implantation techniques and many only take narcotic medication for the first 48–72 hours. All patients undergoing this procedure must be informed that intraoperative conversion to an alternate incision is a rare possibility. There were no instances of conversion during the study period.

The prepectoral placement of implants is done occasionally with TUBA in our practice. Meticulous attention to pocket creation is key in preventing inadvertent passage retropectorally. The endoscope is invaluable in this regard. The endoscope allows you to check the passage of the instruments incrementally as the tunnel is advanced. Finding that the retropectoral pocket has been mistakenly developed creates technical problems in redirecting the implant so formidable that conversion to an alternate technique is recom-

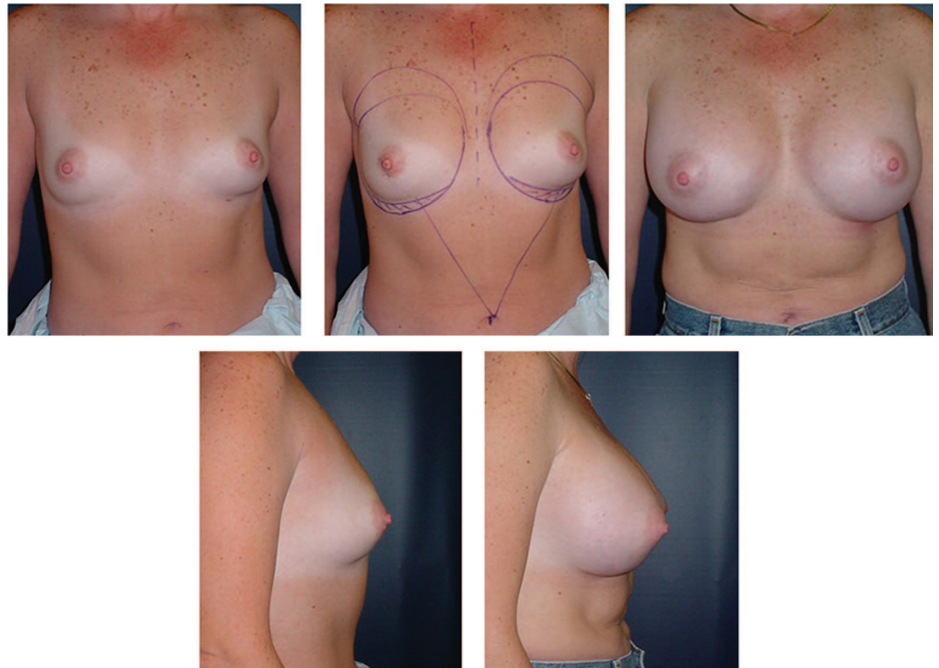


FIGURE 4. Preoperative and 90 days postoperative photos of a 40-year-old nulliparous WF who desired 480-mL saline implants through a transumbilical route. Above, left, preoperative frontal view. Above, center, preoperative frontal view after placement of surgical planning markings. Cross-hatched areas demarcate lowering of inframammary fold 1.5 cm. Above, right, postoperative frontal view. Below, left, preoperative lateral view. Below, right, postoperative lateral view.

mended for surgeons new to this technique. The ideal candidates for this procedure are women that desire a larger breast size whether they never developed the size or have lost volume in their breast through postpartum atrophy, weight loss, or aging and are void of any major procedural scars in the abdomen or breast. Contraindications for this technique are abnormal thoracic cages making easy passage of straight instruments difficult, severe pectus excavatum or pectus carinatum. Relative contraindications are fairly recent (within the last 12 months) abdominoplasty, abdominal liposuction, and other procedures leading to fibrosis and scarring of the abdominal or thoracic regions. Women who have a rib cage anatomy which is flaring in nature tend to make passage of the instruments problematic. Although implants can and have been removed through the transumbilical approach, damage to the implant upon removal is inevitable and may be more time consuming than other approaches. These authors have used the umbilical incision as not only the route for primary augmentation, but also for replacement of deflated implants, moderate changes in implant size with implant replacement, correction of asymmetries with placement of Spectrum implants and in combination with other procedures such as abdominoplasty and mastopexy. Satisfaction surveys are albeit subjective and incorporate a plethora of variables into the patients' opinion but are nevertheless useful in monitoring any changes made to a practice or a procedure.¹⁵ These results are supportive of the idea that this technique has the potential to produce satisfied patients in practices other than our own. We firmly believe that, in the end, cosmetic surgery procedures that are safe, effective, and reproducible ultimately are measured by patient satisfaction.

Lowering the Inframammary Fold

Sudarsky¹⁶ claimed in 2001 that although the TUBA could be performed prepectorally and retropectorally, a draw-

back of the procedure was that the inframammary fold could not be lowered. This author wishes to convey that the gradual blunt dissection technique inherent to TUBA allows for safely lowering of the inframammary fold up to 2.5 cm in either the prepectoral or retropectoral case. Before and after photos of 2 such cases are presented in Figures 3 and 4.

CONCLUSION

TUBA is a procedure with risks, limitations, and caveats and has repeatedly proven itself as being worthy of the respectful learning curve associated with it. It has enjoyed a growing popularity among surgeons and no doubt will continue this trend in the future. The benefits of this technique may outweigh the challenges in many cosmetic patients, and the results we have presented here stand in support of its safety and the satisfaction it has brought to our patients.

REFERENCES

1. Johnson GW, Christ JE. The endoscopic breast augmentation: The transumbilical insertion of saline-filled breast implants. *Plast Reconstr Surg.* 1993;92:801.
2. Momeni A, Padron NT, Fohn M, et al. Safety, complications, and satisfaction of patients undergoing submuscular breast augmentation via the inframammary and endoscopic transaxillary approach. *Aesthetic Plast Surg.* 2005;29:558–564.
3. Safian LS. Cosmetic rhinoplasty: radiological features. *Head Neck Surg.* 1984;7:139–149.
4. Dowden RV. Dispelling the myths and misconceptions about transumbilical breast augmentation. *Plast Reconstr Surg.* 2000;106:190–196.
5. Dowden RV. Keeping the transumbilical breast augmentation procedure safe. *Plast Reconstr Surg.* 2000;106:190–194.
6. Caleel RT. Transumbilical endoscopic breast augmentation: submammary and subpectoral. *Plast Reconstr Surg.* 2000;106:1177–1182.
7. Tebbetts JB. Augmentation mammoplasty: patient evaluation, operative planning, and surgical techniques to increase control and reduce morbidity and reoperations in breast augmentation. *Clin Plast Surg.* 2001; 28:501–521.
8. Schlesinger SL, Ellenbogen R, Desvigne MN, et al. Zafirlukast (Acco-

- late): a new treatment for capsular contracture. *Aesthetic Surg J.* 2002;22:329–336.
9. Inamed Corporation. *2004 Update: Making an Informed Decision: Saline-Filled Breast Implant Surgery.* Inamed Aesthetics, Inamed Corporation; 2005.
 10. Songcharoen S. Endoscopic transumbilical subglandular augmentation mammoplasty. *Clin Plast Surg.* 2002;29:1–13.
 11. Brachman PS, Dan BB, Haley RW, et al. Nosocomial surgical infections: incidence and cost. *Surg Clin North Am.* 1980;60:15–25.
 12. Okwueze M, Spear M, Zwyghuizen A, et al. Effect of augmentation mammoplasty on breast sensation. *Plast Reconstr Surg.* 2006;117:73–83.
 13. Adams W, Rios J, Smith S. Enhancing patient outcomes in aesthetic and reconstructive breast surgery using triple antibiotic breast irrigation: six year prospective study. *Plast Reconstr Surg.* 2006;117:30–35.
 14. Henriksen TF, Fryzek JP, Holmich LR, et al. Surgical intervention and capsular contracture after breast augmentation: a prospective study of risk factors. *Ann Plast Surg.* 2005;54:343–351.
 15. Haiavy J, Tobin HA. Augmentation mammoplasty with saline-filled textured implants: review of 9 years' experience and results of patient survey. *Am J Cosmetic Surg.* 2002;19:15–20.
 16. Sudarsky L. Experience with transumbilical breast augmentation. *Ann Plast Surg.* 2001;46:467–473.